



# A Teleradiology System for Early Ischemic and Hemorrhagic Stroke Evaluation and Management

Arjun Kalyanpur<sup>1</sup> Neetika Mathur<sup>2</sup>

<sup>1</sup>Teleradiology Solutions, Plot No. 7G, Opposite Graphite India, Whitefield, Bengaluru, Karnataka, India

<sup>2</sup>Image Core Lab, Plot No. 7G, Opposite Graphite India, Whitefield, Bengaluru, Karnataka, India

**Address for correspondence** Neetika Mathur, PhD, Image Core Lab, Plot No. 7G, Opposite Graphite India, Whitefield, Bengaluru, Karnataka 560048, India (e-mail: neetika.mathur@imagecorelab.com).

J Clin Interv Radiol ISVIR

## Abstract

**Purpose** Stroke is a cardinal cause of death and disability globally. It is an emergency condition where the rapidity of diagnosis is directly linked to the outcome. “Imaging is Brain” is, therefore, an important concept. The early diagnosis of stroke is crucial not only in guiding its effective treatment but also in estimating prognosis. This study aims to provide perspective on the implementation of international teleradiology in stroke evaluation, management, and care.

**Methods** A dedicated international teleradiology stroke network has been evaluated in our study between March 2019 and July 2022 where the interpretation and analysis of the computed tomography (CT) scans of the patients from distant hospitals in United States were performed by teleradiologists via high-quality Digital Imaging and Communications in Medicine (DICOM)-image transfer through a cloud-based radiology information system/picture archival and communication system platform RADspa.

**Results** Over a period of three and a half years, starting from March 2019, a total of 30,406 CT scans of 19,342 patients from 96 hospitals of 15 states in the United States were interpreted and reported by board-certified radiologists empaneled by Teleradiology Solutions. The mean report turnaround time for all noncontrast CT studies was 9.97 minutes at 95% confidence interval (CI: 9.89–10.05); for CT angiogram studies, it was 20.57 minutes 95% CI (20.38–20.77); and for CT perfusion studies, it was 13.72 minutes 95% CI (13.42–14.03).

**Conclusion** A dedicated international teleradiology stroke network designed in our study allowed for transmission, prioritization, evaluation, and management of CT cases performed in the setting of acute stroke in the study population. The results of our investigation indicate that teleradiology provides an effective solution for early diagnosis/interpretation of CT examinations performed internationally in the setting of acute stroke. This may further be used as a model or template for the development of a nationwide stroke network within our own country.

## Keywords

- ▶ stroke
- ▶ turnaround time
- ▶ teleradiology

DOI <https://doi.org/10.1055/s-0043-1771379>.  
ISSN 2457-0214.

© 2023. Indian Society of Vascular and Interventional Radiology. All rights reserved.

This is an open access article published by Thieme under the terms of the Creative Commons Attribution-NonDerivative-NonCommercial-License, permitting copying and reproduction so long as the original work is given appropriate credit. Contents may not be used for commercial purposes, or adapted, remixed, transformed or built upon. (<https://creativecommons.org/licenses/by-nc-nd/4.0/>)

Thieme Medical and Scientific Publishers Pvt. Ltd., A-12, 2nd Floor, Sector 2, Noida-201301 UP, India

## Introduction

Stroke is a cardinal cause of death and disability (combinedly described by disability-adjusted life-years lost—) globally. The global cost of stroke is estimated to be over US\$891 billion (1.12% of the global gross domestic product).<sup>1,2</sup> In India, it is the fourth leading cause of death and the fifth main cause of disability. The studies propose that the crude incidence rates of stroke in India span between 108 and 172 per one lakh persons per year.<sup>3,4</sup>

A stroke (colloquially known as a brain attack) is the rapid loss of brain functions due to a blockage or leakage in a blood vessel supplying and draining blood to and from the brain. According to a cooperative study coordinated by the World Health Organization, stroke was defined as rapidly developing clinical signs of (usually focal or global) disturbance of cerebral function lasting more than 24 hour or leading to death.<sup>5</sup> Among different types of strokes, one is the “ischemic” stroke that is caused by a lack of oxygen and nutrients supplied to brain cells (ischemia) due to a blocked artery (thrombosis or arterial embolism). The other is a “hemorrhagic” stroke, which occurs due to the rupture of the blood vessel causing bleeding within the brain. The blood accumulates and compresses the surrounding brain tissue. About 87% of strokes are ischemic strokes. Sometimes, temporary obstruction of blood vessels causes a transient ischemic attack, sometimes referred to as a mini-attack.<sup>6</sup>

The early diagnosis of stroke is crucial not only in guiding its effective treatment but also in estimating prognosis. “Time is brain” is a crucial concept in the case of stroke patients because, with each minute of stroke unaddressed, about two million neurons die. It is a medical emergency where the golden hour of less than 60 minutes from the onset of the symptom is pivotal. During this interval, health professionals should make prudent diagnostic and treatment solutions as rapidly, proficiently, and effectively as possible.<sup>7,8</sup> Stroke patients may sometimes ignore signs such as sudden onset weakness or numbness. The prominent symptoms of stroke are numbness, visual loss or blurred vision, sensory deficits, impaired consciousness, dizziness, vertigo, loss of balance, dysphagia, headache, and speech problems.<sup>9</sup> Often minor stroke or transient ischemic attack serves as a warning for subsequent major stroke (cerebrovascular accident).

According to the American Heart Association/American Stroke Association 2018 guidelines, there is a paradigm shift from “Time is Brain” to “Imaging is Brain” in acute stroke management.<sup>10</sup> Treatment decisions for stroke patients require timely evaluation with various ultrafast imaging tools. It should be performed immediately after clinical triage and emergency stabilization of the patient. A variety of imaging techniques such as X-ray radiography, ultrasound, computed tomography (CT), nuclear medicine including positron emission tomography, and magnetic resonance imaging may be used to diagnose stroke. An important early diagnostic test performed at the time of initial presentation, CT scan of the brain determines whether the stroke is hemorrhagic or ischemic. It helps in deciding the line of treatment which

is diametrically opposite for the two conditions. The treatment for ischemic stroke consists of administering blood-thinning medications which dissolve the blood clot that has formed. On the contrary, in hemorrhagic stroke, such blood thinners would actually exacerbate the bleeding and should not be used. The other important advanced imaging techniques such as CT angiography (CTA) can help in identifying the blocked vessel and other vascular abnormalities such as arteriovenous malformation that are prone to hemorrhage. CT perfusion determines the amount of brain tissue that has already been irreversibly damaged (called infarct core) and salvageable ischemic brain tissue that is at potential risk of damage (penumbra).<sup>11</sup> It is performed to guide the treatment of patients where the time of stroke onset is unknown or when the patient could not communicate due to aphasia.<sup>12</sup>

There is a severe paucity of trained radiologists and stroke care specialists. Besides that, the probability of having a radiologist on site at a hospital at the same time when a stroke patient arrives is not always guaranteed. However, technological advancements specifically teleradiology have provided improved collaboration, communication, and consultation with doctors, leading to better patient care. Teleradiology has effectively contributed and has in fact transformed stroke care. This technology finds its roots dating back to 1947 starting with the transmission of radiographic images by telephone lines.<sup>13</sup> With the advent of the Internet and the picture archiving and communications system (PACS), teleradiology began to initially make impact and today it is well established and in widespread use in the healthcare sector. The teleradiology services play a significant role in stroke care by providing prompt, timely, quality and accurate radiologic interpretation of the patients imaging. Stroke protocol cases are assigned with highest prioritization and fastest turnaround time (TAT) target of within 15 minutes for noncontrast computed tomography (NCCT) and 30 minutes for CTA. The TAT is the time elapsed once the images have been received in the telereporting platform and the report sent or verbally communicated to the physicians at the client hospital.

Teleradiology services can ameliorate the shortage of expert radiologists and enhance outcomes of patient care. This study aims to provide perspective on the implementation of international teleradiology in stroke evaluation, management, and care and develop insights for a similar model in India.

## Materials and Methods

The study was performed between March 2019 and July 2022 and involved analysis of stroke imaging studies originating from 96 hospitals from 15 states of the United States by a teleradiology service provider, Teleradiology Solutions, headquartered in Bangalore, India, which employs US board-certified radiologists distributed across the globe. The DICOM images of the NCCT, CTA, and CT perfusion brain scans of suspected stroke patients were uploaded onto the telereporting workflow platform “RADspa,” a cloud-based

radiology information system (RIS)/ PACS system over a high-speed Internet connection, generating a worklist. The images were interpreted by board-certified radiologists empaneled with Teleradiology Solutions and the reports were transmitted back to the client hospitals over the same workflow platform, as well as verbally/telephonically. Other information such as prior images and reports, patient clinical, and surgical history records were also uploaded into the RIS so that they were available to the radiologists along with the images.

NCCT brain scans were evaluated for the detection of hemorrhage and early signs of infarction, which include early parenchymal ischemic changes and dense vessels indicating thrombosis. To guide and standardize the interpretation of CT scans among radiologists and referring physicians, the ASPECTS (Alberta Stroke Program Early CT Score) was also used in some cases, as a quantitative score to determine the extent of early ischemic changes in the middle cerebral artery (MCA) territory on NCCT on a scale of 1 to 10. CTA brain scans were evaluated for intracranial vessel occlusion and aneurysm. CT perfusion scans were evaluated for infarct and ischemic penumbra. An approval from the Institutional Review Board has been taken.

### Results

Over a period of three and a half years, starting from March 2019, a total of 30,406 CT scans of 19,342 patients presenting with acute stroke-like symptoms from 96 hospitals of 15 states in the United States were uploaded to the

RADspa cloud server and interpreted by board-certified radiologists empaneled by Teleradiology Solutions (►Fig. 1).

The information about the demographics such as gender and age of the patients were also loaded into the cloud-based server (►Table 1). The mean age of the patients was 66 years. The maximum number of patients in the study belonged to age group of 61 to 80 years (►Fig. 2).

The suspected stroke patients underwent diagnostic imaging including NCCT head, CTA, and CT perfusion. About 56.2% patients had undergone a single imaging (NCCT or CTA or CT perfusion), while 42.7% patients had undergone multiple imaging studies (►Fig. 3).

The total number of imaging studies performed was 30,406, out of which 4,621 studies had stroke positive findings. The maximum number of studies were NCCT head scans (16,950). The number of CTA and CT perfusion studies were 10,886 and 2,570, respectively. Out of 16950 NCCT studies, 1992 studies were diagnosed to be stroke positive, while 1941 CTA studies and 688 CT perfusion studies had positive findings, respectively.

Among all of the NCCT head scans that were analyzed for the type of hemorrhagic stroke, 667 studies were diagnosed with intraparenchymal hemorrhage (IPH) (bleeding within brain parenchyma), 425 had subarachnoid hemorrhage (SAH) (hematoma arising between arachnoid and pia mater), 420 had subdural hemorrhage (bleeding in between dura and arachnoid membranes), and 372 had intraventricular hemorrhage (bleeding takes place in the ventricles of the brain) (►Fig. 4). Five-hundred twenty-eight studies showed dense MCA on NCCT head.

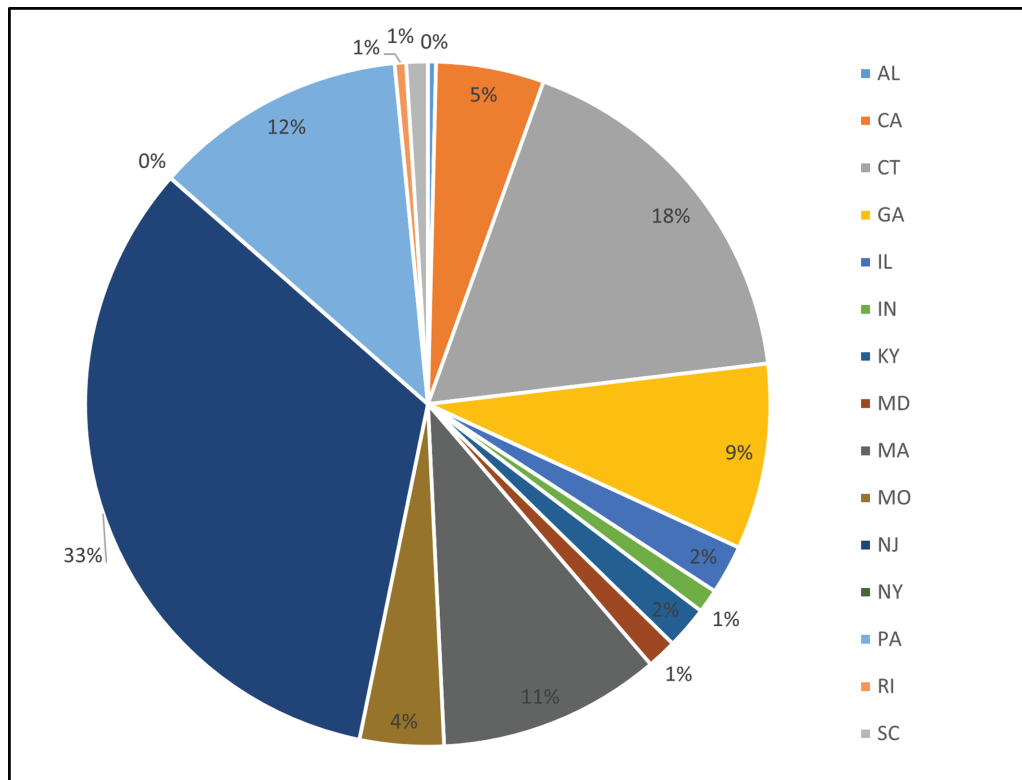


Fig. 1 Comparative plot of percentage of computed tomographic studies received from the hospitals of different states of United States.

**Table 1** Age and gender statistics for the overall study population (n = 19, 342)

Demographics		n (%)
1. Gender	Female	10,138 (52.42%)
	Male	9,204 (47.58%)
2. Mean age in years (range)		66 (2 to 103)

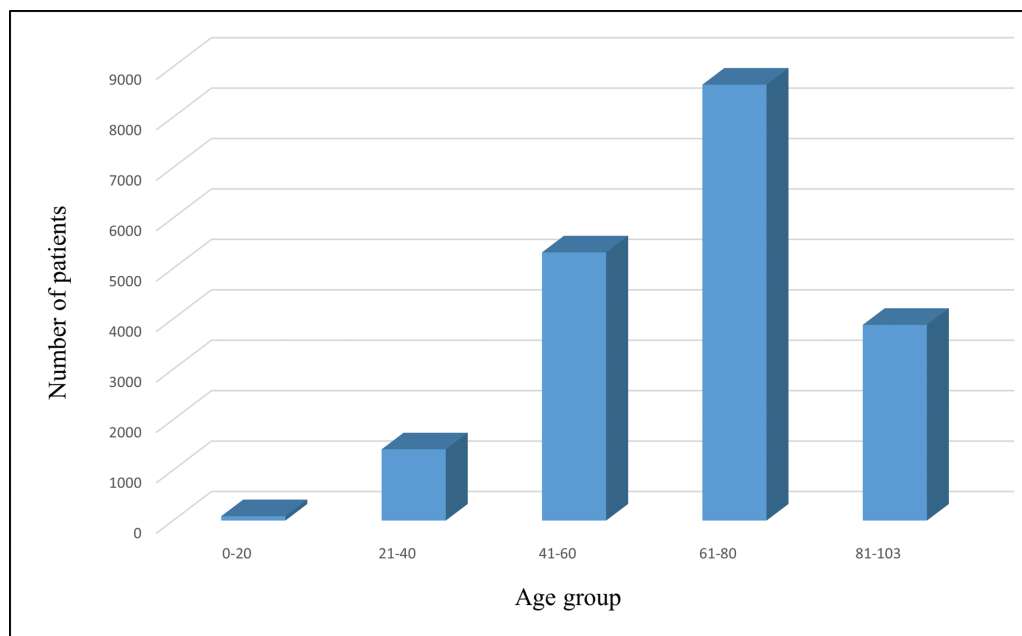
CTA were evaluated to determine any intracranial vessel occlusion and aneurysm. Out of 10,886 CTA studies, 1,616 studies were positive for the large vessel occlusion (LVO) and 373 studies were positive for aneurysm. Maximum number of studies (758) were diagnosed with occlusion in MCA (→Fig. 5). Among 2,570 CT perfusion studies, 383 studies were diagnosed with acute infarct, 140 studies with ischemia, and 311 studies demonstrated ischemic penumbra.

The ASPECTS was also used in some cases (1459) as a valuable technique to guide and evaluate the prognosis in acute ischemic stroke. Among 1,459 cases that were evaluated for ASPECTS score, a small number of cases (20) had a score of less than or equal to 6 (→Fig. 6).

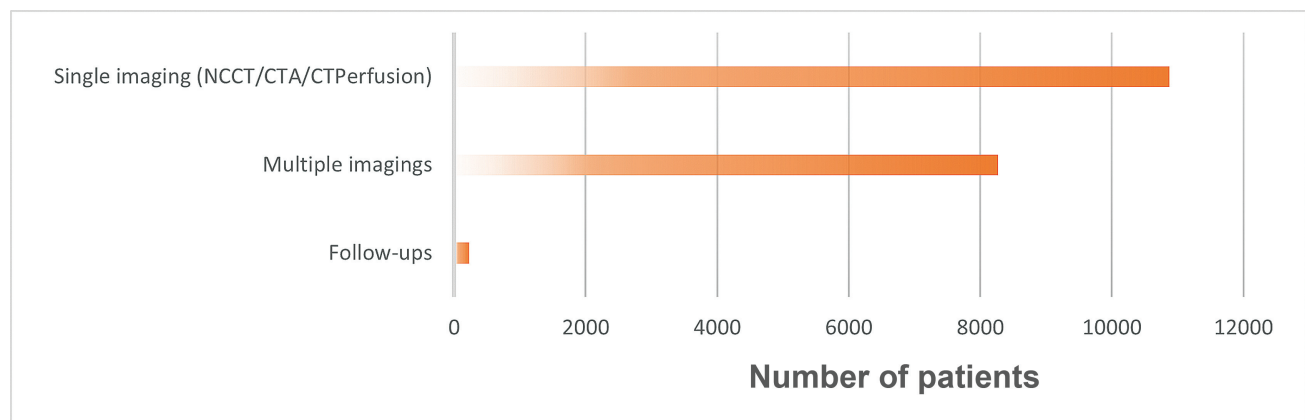
The mean reporting TAT for all NCCT studies was 9.97 minutes at 95% confidence interval (CI: 9.89–10.05); for CTA studies, it was 20.57 minutes 95% CI (20.38–20.77); and for CT perfusion studies, it was 13.72 95% CI (13.42–14.03).

### Discussion

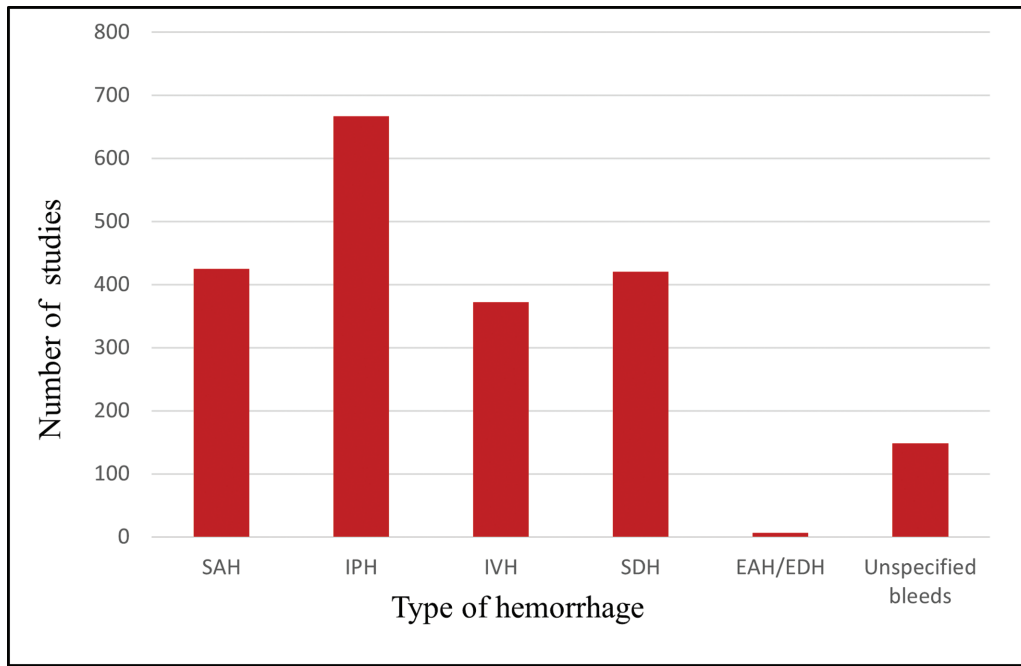
Our study indicates effective utilization of teleradiology in identification, evaluation, and management of stroke cases in the study population. The telehealth model systems for stroke have been validated in earlier studies.<sup>14,15</sup> Mitchell et al have reported a teleradiology system for primary diagnosis of acute stroke, based on a client-server architecture that provides



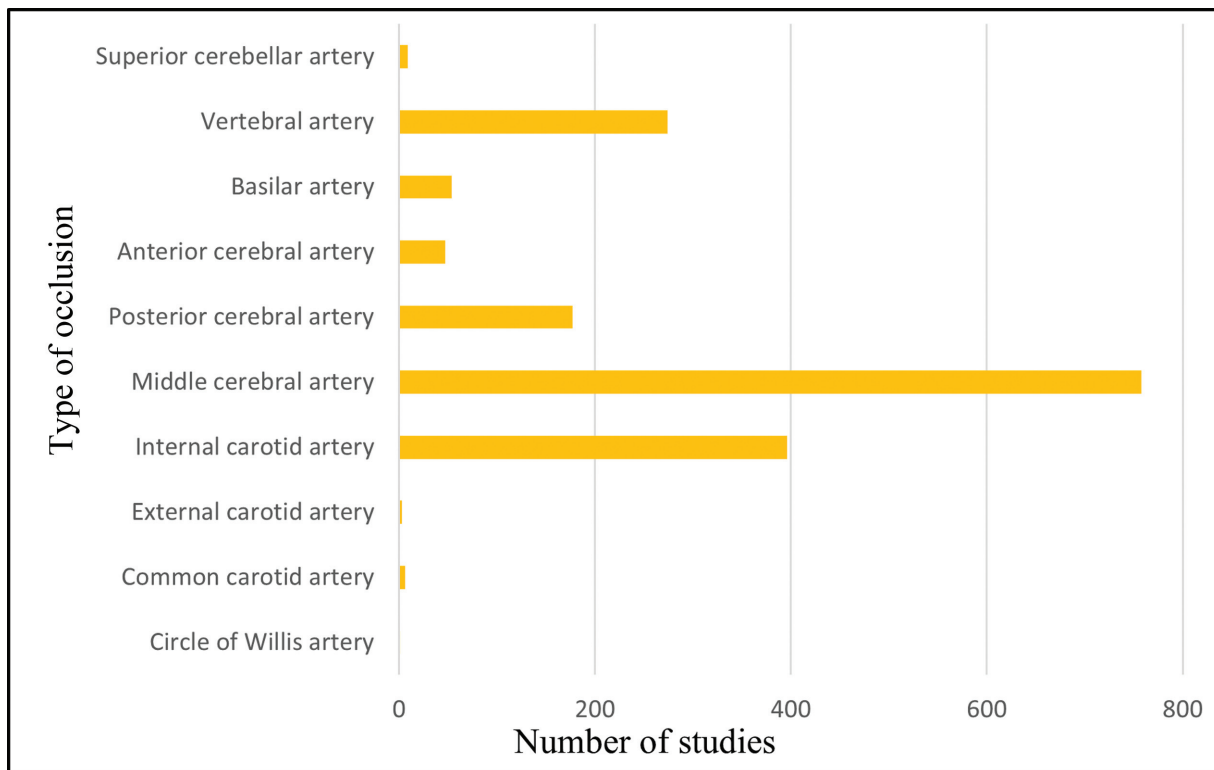
**Fig. 2** Age group categorization of patients.



**Fig. 3** Comparative plot of the number of patients undergone single and multiple imaging and follow-up. CTA, computed tomography angiography; NCCT, noncontrast computed tomography.



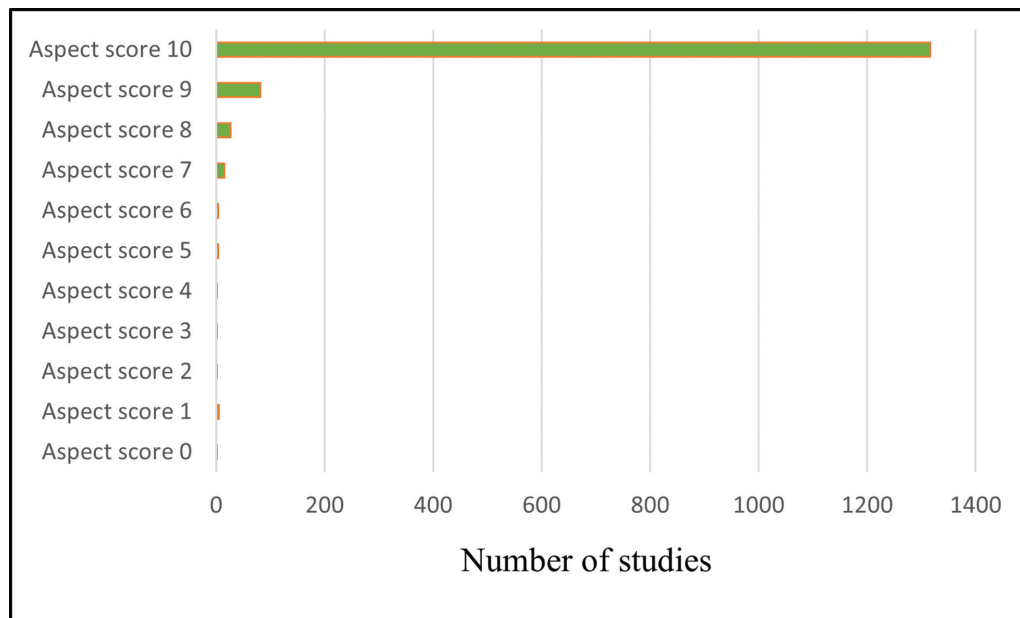
**Fig. 4** Comparative plot of the number of noncontrast computed tomography studies with different types of hemorrhage. EAH/EDH, extra-axial hemorrhage/extradural hemorrhage; IPH, intraparenchymal hemorrhage; IVH, intraventricular hemorrhage; SAH, subarachnoid hemorrhage; SDH, subdural hemorrhage.



**Fig. 5** Comparative plot of the number of computed tomography angiography studies with different types of blood vessel occlusions.

quick access to radiological images on a current-generation smartphone. Pohjonen et al reported that the use of computing grids and handheld or wireless devices provides clinicians access to all patient data and analysis tools and is transforming the workflows in healthcare enterprises.<sup>16</sup> Our international teleradiology model involved transmission of DICOM images

of scans of patients located in United States through RADspa, a cloud-based RIS-PACS workflow platform, which was accessed, interpreted, and reported by the radiologists in Bangalore. This model is highly useful in the emergency condition such as stroke where the concept of “Time is Brain” is crucial.



**Fig. 6** Alberta Stroke Program Early CT (ASPECTS) score categorization of the cases.

In our study, the maximum number of patients were in the age group of 61 to 80 years. A similar study conducted by Konduru et al suggested the highest number of stroke cases was in the age group 50 to 70 that is due to the presence of a greater number of risk factors like chronic diseases (hypertension) among the cases.<sup>17</sup> Previous studies also correlate with our analysis of mean age of the stroke patients being 66 years.

A well-defined imaging protocol helps in better management of stroke in emergency settings. Hemorrhagic stroke raises a significant healthcare concern since it results in high mortality and has significant impact on the survivors' quality of life. Treatment strategies and clinical outcomes are heavily reliant on the size, spread, and location of the hemorrhage.<sup>18</sup> For hemorrhagic stroke diagnosis, NCCT is the primary neuroimaging modality. During our study, the analysis of NCCT head scans revealed that among different types of hemorrhagic strokes, maximum studies (667) were diagnosed with IPH. Similar results were also obtained in a study conducted by Mullins et al where the most common type of intracranial hemorrhage was intraparenchymal, where hypertension and cerebral amyloid angiopathy were found to be the main risk factors for primary IPH.<sup>19</sup>

The dense MCA sign is considered as a vital diagnostic tool for acute stroke as it is the first visible sign of presence of thromboembolic material within the lumen of the MCA.<sup>20</sup> In our study, 528 cases demonstrated dense MCA on brain NCCT.

Early diagnosis and an accurate assessment of the location of the LVO through CTA in patients suspected with ischemic stroke are critical for issuance of timely, optimal, and appropriate treatment opportunity such as intravenous or intra-arterial thrombolysis and mechanical thrombectomy.<sup>21</sup> In our study, maximum studies (758) had LVO in MCA. CTA were also evaluated for the presence of aneurysm. Three-hundred seventy-three cases in our study showed the presence of an aneurysm.

ASPECTS is considered as a key imaging technique used for the selecting the patients with greatest extent of ischemic damage for endovascular therapies.<sup>22</sup> The updated American Heart Association guidelines on the management of acute stroke recommended endovascular therapy in patients with baseline ASPECTS more than or equal to 6. An ASPECTS score less than or equal to 7 predicts a worse functional outcome at 3 months. Among 1,459 cases that were evaluated for ASPECTS score, very few cases (20) had a score of less than or equal to 6.

Time is pivotal for the management of the stroke patient, starting from the imaging of the patient until the initiation of therapy, including intravenous thrombolytic therapy and mechanical thrombectomy.<sup>23</sup> According to the guidelines given by the American Heart Association and American Stroke Association, the imaging of suspected stroke patients must be performed within 20 minutes of their arrival. Further for rapid interpretation and reporting by radiologists, stroke protocol cases are designated with highest priority. Teleradiology Solutions, a teleradiology service provider, followed a protocol for reporting NCCT cases and perfusion CT within 15 minutes of TAT and CTA within 30 minutes of TAT. The mean TAT for all NCCT cases in our study was 9.97 minutes at 95% CI (9.89–10.05) that is in compliance with a study conducted by Eagles et al.<sup>24</sup> In those cases where interpretation time exceeded the limits of compliance, the reasons for delay in interpretation were largely process related and included absence of relevant prior images, slow image transmission, errors in the order entry needing correction, delayed order entry, and call put on hold from client hospital during verbal communication.

## Conclusion

Stroke is an emergency condition where timely care of the patient is utmost priority and requires urgent collaborative management decisions by the experts from different

subspecialties, especially a neurologist and a radiologist. This is where teleradiology provides maximum value. American Heart Association/American Stroke Association stroke has also released guidelines which strongly support Food and Drug Administration-approved teleradiology services for acute stroke care.<sup>25</sup> The Government of India has also made an initiative in 2010 through the National Program for Prevention and Control of Cancer, Diabetes, Cardiovascular Diseases & Stroke as part of National Health Mission, the Union Ministry of Health & Family Welfare for the early diagnosis, management, public awareness, infrastructure, and capacity building for noncommunicable diseases including stroke at different levels of health care system.<sup>26</sup> A dedicated international teleradiology stroke network designed in our study allowed the interpretation and analysis of the CT scans of the stroke patient from a distant hospital in United States by a teleradiologist via high-quality DICOM-image transfer through a cloud-based platform. The results of our investigation indicate that teleradiology provides an effective solution for early diagnosis/interpretation of CT examinations performed internationally in the setting of acute stroke. This may further be used as a model or template for the development of a nationwide stroke network within our own country.

#### Ethical Approval

This retrospective study has been approved by the institutional review board (IRB).

#### Conflict of Interest

None declared.

#### References

- Feigin VL, Brainin M, Norrving B, et al. World Stroke Organization (WSO): Global Stroke Fact Sheet 2022. *Int J Stroke* 2022;17(01):18–29
- GBD 2019 Stroke Collaborators. Global, regional, and national burden of stroke and its risk factors, 1990–2019: a systematic analysis for the Global Burden of Disease Study 2019. *Lancet Neurol* 2021;20(10):795–820
- Jones SP, Baqai K, Clegg A, et al. Stroke in India: a systematic review of the incidence, prevalence, and case fatality. *Int J Stroke* 2022;17(02):132–140
- Accessed July 3, 2023 at: <https://www.dailypioneer.com/2018/columnists/india-s-stroke-epidemiology.html>
- Aho K, Harmsen P, Hatano S, Marquardsen J, Smirnov VE, Strasser T. Cerebrovascular disease in the community: results of a WHO collaborative study. *Bull World Health Organ* 1980;58(01):113–130
- Types of Stroke and Treatment Accessed July 3, 2023 at: <https://www.stroke.org/en/about-stroke/types-of-stroke>
- Akbarzadeh MA, Sanaie S, Kuchaki Rafsanjani M, Hosseini MS. Role of imaging in early diagnosis of acute ischemic stroke: a literature review. *Egypt J Neurol Psychiat Neurosurg* 2021;57(01):175. Doi: 10.1186/s41983-021-00432-y
- Advani R, Naess H, Kurz MW. The golden hour of acute ischemic stroke. *Scand J Trauma Resusc Emerg Med* 2017;25(01):54. Doi: 10.1186/s13049-017-0398-5
- Di Stefano V, De Angelis MV, Montemiro C, et al. Clinical presentation of strokes confined to the insula: a systematic review of literature. *Neurol Sci* 2021;42(05):1697–1704
- Puig J, Shankar J, Liebeskind D, et al. From “Time is Brain” to “Imaging is Brain”: a paradigm shift in the management of acute ischemic stroke. *J Neuroimaging* 2020;30(05):562–571
- Accessed July 3, 2023 at: <https://timesofindia.indiatimes.com/blogs/voices/how-artificial-intelligence-and-teleradiology-can-be-used-for-early-stroke-diagnosis/>
- Birenbaum D, Bancroft LW, Felsberg GJ. Imaging in acute stroke. *West J Emerg Med* 2011;12(01):67–76
- Bashshur RL, Krupinski EA, Thrall JH, Bashshur N. The empirical foundations of teleradiology and related applications: a review of the evidence. *Telemed J E Health* 2016;22(11):868–898
- Mitchell JR, Sharma P, Modi J, et al. A smartphone client-server teleradiology system for primary diagnosis of acute stroke. *J Med Internet Res* 2011;13(02):e31. Doi: 10.2196/jmir.1732
- Demaerschalk BM, Vargas JE, Channer DD, et al. Smartphone teleradiology application is successfully incorporated into a telestroke network environment. *Stroke* 2012;43(11):3098–3101
- Pohjonen H, Ross P, Blickman JG, Kamman R. Pervasive access to images and data—the use of computing grids and mobile/wireless devices across healthcare enterprises. *IEEE Trans Inf Technol Biomed* 2007;11(01):81–86
- Konduru SST, Ranjan A, Nallajerla JS, et al. Study of symptoms, risk factors and prescribing patterns in cerebral stroke patients. *Indian Journal of Pharmacy Practice* 2017;10(01):20–26
- Chinda B, Medvedev G, Siu W, et al. Automation of CT-based haemorrhagic stroke assessment for improved clinical outcomes: study protocol and design. *BMJ Open* 2018;8(04):e020260. Doi: 10.1136/bmjopen-2017-020260
- Mullins ME, Lev MH, Schellingerhout D, Gonzalez RG, Schaefer PW. Intracranial hemorrhage complicating acute stroke: how common is hemorrhagic stroke on initial head CT scan and how often is initial clinical diagnosis of acute stroke eventually confirmed? *AJNR Am J Neuroradiol* 2005;26(09):2207–2212
- Chen RJ, Wei G, Dense MCA Sign. *Journal of Education and Teaching in Emergency Medicine* Published online 2017. Doi: 10.21980/J8CS66
- Lakomkin N, Dhmoon M, Carroll K, et al. Prevalence of large vessel occlusion in patients presenting with acute ischemic stroke: a 10-year systematic review of the literature. *J Neurointerv Surg* 2019;11(03):241–245
- Pop NO, Tit DM, Diaconu CC, et al. The Alberta Stroke Program Early CT score (ASPECTS): a predictor of mortality in acute ischemic stroke. *Exp Ther Med* 2021;22(06):1371. Doi: 10.3892/etm.2021.10805
- Trongnit S, Reesukumal K, Kost GJ, Nilanont Y, Pratumvinit B. Reducing laboratory turnaround time in patients with acute stroke and the lack of impact on time to reperfusion therapy. *Arch Pathol Lab Med* 2023;147(01):87–93
- Eigles S, Panughpath SG, Kalyanpur A. Enhancing turn-around-time (TAT) on stroke protocol head CT reports via continuous quality improvement (CQI) methodology in a busy teleradiology practice. *Am J Exp Clin Res* 2015;2:102–104
- Solenski NJ. Telestroke. *Neuroimaging Clin N Am* 2018;28(04):551–563
- Accessed July 3, 2023 at: [https://dghs.gov.in/content/1363\\_3\\_National-ProgrammePreventionControl.aspx#:~:text=The%20Government%20of%20India%20has,under%20the%20National%20Health%20Mission](https://dghs.gov.in/content/1363_3_National-ProgrammePreventionControl.aspx#:~:text=The%20Government%20of%20India%20has,under%20the%20National%20Health%20Mission)