

# Bowel Anastomotic Leaks: A Pictorial Review of Salient Findings on Computed Tomography (CT)

## Pictorial Review Article

Shipra Kumari<sup>1\*</sup>, Pallavi Rao<sup>2</sup> and Arjun Kalyanpur<sup>3</sup>

<sup>1</sup>Consultant Radiologist, Teleradiology Solutions, Whitefield, Bangalore, India

<sup>2</sup>Senior Scientific Officer, Image Core Lab, Whitefield, Bangalore, India

<sup>3</sup>Chief Radiologist, Teleradiology Solutions, Whitefield, Bangalore, India

**\*Corresponding author:** Shipra Kumari, Consultant Radiologist, Teleradiology Solutions, Whitefield, Bangalore, India  
Email:shipra.kumari@telradsol.com

**Copyright:** © 2025 Kumari S, et al. This is an open access article distributed under the Creative Commons Attribution License, which permits unrestricted use, distribution, and reproduction in any medium, provided the original work is properly cited.

**Article Information:** Submission: 01/04/2025; Accepted: 15/05/2025; Published: 20/05/2025

### Abstract

**Background:** Anastomotic leaks can occur in early and late post-operative phase when enteric anastomosis fails. Undiagnosed anastomotic leak carries a poor outcome. Therefore, knowledge of accurate interpretation of CT imaging characteristics is vital for a timely and accurate diagnosis of anastomotic leak.

**Aims and objectives:** The purpose of this study is to assess the salient imaging findings of bowel anastomotic leak on Computed Tomography and compile a pictorial review useful in the identification of anastomotic leaks after gastrointestinal tract surgery.

**Materials and Methods:** We retrospectively evaluated 49 CT abdomen and pelvis studies which were diagnosed to have post-surgical anastomotic leak as based on keyword search from Emergency Teleradiology reports. Out of 49 cases, non-contrast (17), IV contrast (17), oral contrast (4), oral and IV contrast (10) and rectal contrast (1) were identified. The results were analysed and compiled in a pictorial review.

**Results:** Our study demonstrated that extraluminal air was the most common imaging finding seen in 14.21% of patients. Focal collection or abscess (13.7%), peritonitis in (12.3%), bowel wall thickening (5.4%) and intra-abdominal free fluid (2.9%) of examinations. Few other imaging findings included entero-cutaneous fistula in 2% of the cases and bowel obstruction in one case. Out of 14 examinations performed after administration of enteric contrast, 10 cases were positive for extravasation of intra-luminal contrast.

**Conclusion:** Early intervention in patients with anastomotic leak has shown to improve the ultimate outcome, especially with respect to mortality. Abdominal CT is a highly accurate non-invasive test in the detection of anastomotic leak.

**Keywords:** Anastomotic Leak; Peritonitis; Free Fluid; Bowel Wall Thickening

## Introduction

Anastomotic leaks are one of the most serious post-operative complications that can occur after a bowel surgery [1]. Anastomotic leaks can occur in early and late post-operative phases when enteric anastomosis fails [2]. The International Study Group of

Rectal Cancer (ISREC) proposed a definition and grading system for colorectal anastomotic leaks in 2010. The ISREC defined a leak as “a defect of the intestinal wall at the anastomotic site (including suture and staple lines of ano-rectal reservoirs) leading to a communication between the intra- and extraluminal compartments.”[3]. The ISREC

delineated leaks by grades A to C based on their clinical management which have been validated [4].

Anastomotic leaks following bowel surgery can be classified into various categories, distinguishing between simple fistulas and large sinuses, as well as intra-peritoneal and extra-peritoneal occurrences. These leaks may exhibit sepsis-producing symptoms or remain asymptomatic, and their timing can be either early or late post-operative period [5]. Detecting an anastomotic leak relies on clinical suspicion and subsequent diagnostic investigations. When located within the peritoneal cavity, leaks are more likely to manifest with diffuse contamination, peritonitis, and sepsis. On the other hand, extra-peritoneal leaks may present in a less obvious manner, possibly appearing as a fistula, rectal drainage, pain, or even urinary symptoms. Understanding the diverse manifestations of anastomotic leaks is crucial for the timely and accurate management of this serious post-operative complication [6, 7]. The most consistent and significant risk factor for an anastomotic leak is the anatomic site of anastomosis [8]. The risk is higher with distal anastomotic sites. An ileocolic anastomosis has a leak rate of 1-4% as compared to colorectal anastomosis which carries a risk of 0.5-18% and colo-anal anastomosis which carries a risk of 5-19%[9]. Undiagnosed anastomotic leak carries a poor outcome. Therefore, knowledge of accurate interpretation of CT imaging characteristics is vital for a timely and accurate diagnosis of anastomotic leak [10].

### Aims and objectives

- To assess the salient imaging findings of bowel anastomotic leak on CT.
- To compile a pictorial review useful in the identification of anastomotic leaks after gastrointestinal tract surgery.

### Materials and Methods

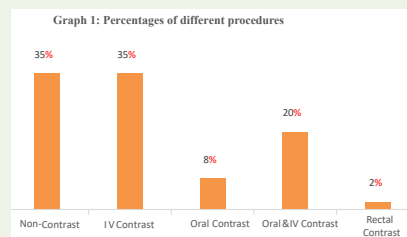
We retrospectively evaluated 49 CT abdomen and pelvis studies which were diagnosed to have post-surgical anastomotic leak based on keyword search from Emergency Teleradiology reports. Images were assessed for salient imaging findings of bowel anastomotic leak. The results were analysed and compiled in a pictorial review.

### Results

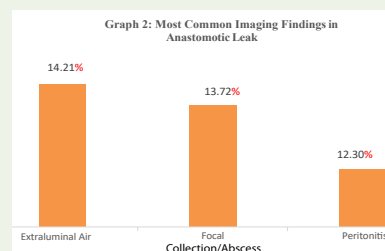
Out of the 49 CT abdomen and pelvis studies, 17 cases were non-contrast and 32 cases were with contrast. Further out of 32 contrast CT cases, 17 cases were IV contrast, 4 cases were oral contrast, and 10 cases were oral and IV contrast and 1 case with rectal contrast. Our study demonstrated that extra-luminal air was the most common imaging finding seen in 14.21% of patients. Other common findings include focal collection or abscess (13.7%), peritonitis (12.3%). Few other uncommon imaging findings includes bowel wall thickening (5.4%), intra-abdominal free fluid (2.9%), and extravasation of intra-luminal contrast (4.9%), bowel obstruction (3.43), contained anastomotic leak (1.47%) and fistula (0.98%).

### Discussion

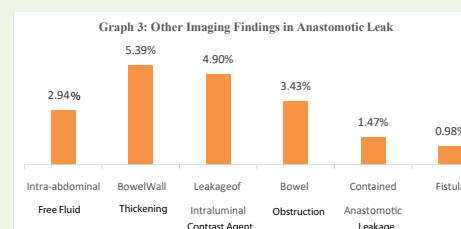
The most important role of imaging patients with suspected



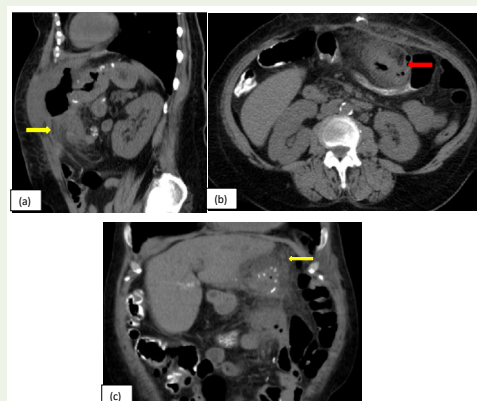
**Graph 1:** The graph represents the contrast and non-contrast CT performed in 49 cases signifying bowel anastomotic leak.



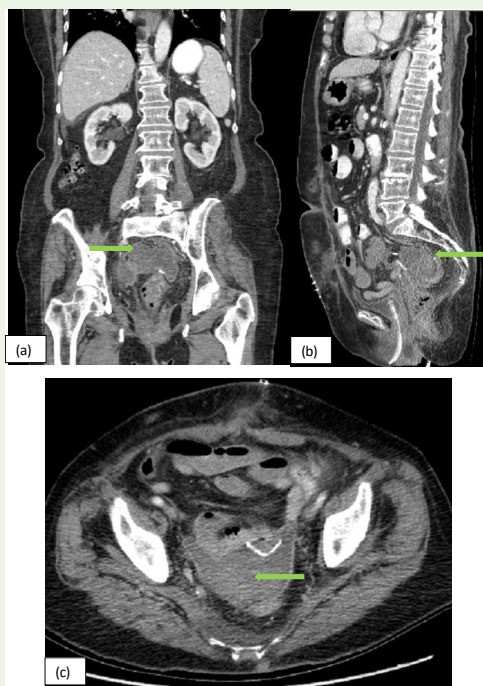
**Graph 2:** The graph represents the percentages of imaging findings. It demonstrates that extra-luminal air was the most common imaging finding seen in 14.21% of patients. Other common findings include focal collection or abscess (13.7%), peritonitis (12.3%).



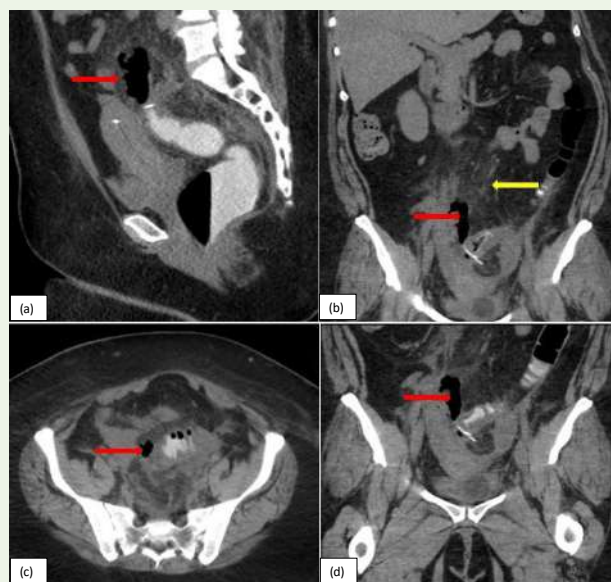
**Graph 3:** The graph represents the few other imaging findings that includes bowel wall thickening (5.4%), intra-abdominal free fluid (2.9%), and extravasation of intra-luminal contrast (4.9%), bowel obstruction (3.43), contained anastomotic leak (1.47%) and fistula (0.98%)



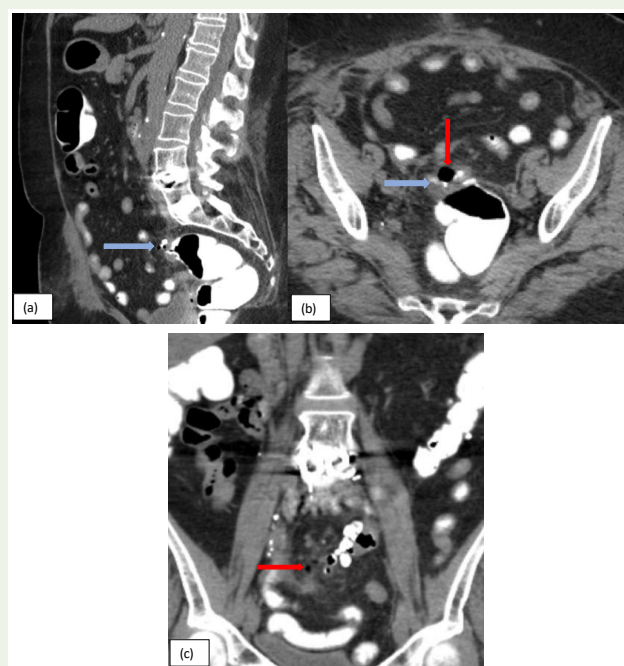
**Figure 1:** (a, b, c): Sagittal, Axial, and Coronal CT images of a 55-year-old female patient presented with c/o abdominal pain. CT scan of the abdomen and pelvis without contrast shows diffuse wall thickening of the stomach/proximal jejunum with a defect at the site of anastomosis and extra-luminal air loculi (red arrow) and fat stranding in the left upper abdomen (yellow arrow), suggestive of anastomotic leak.



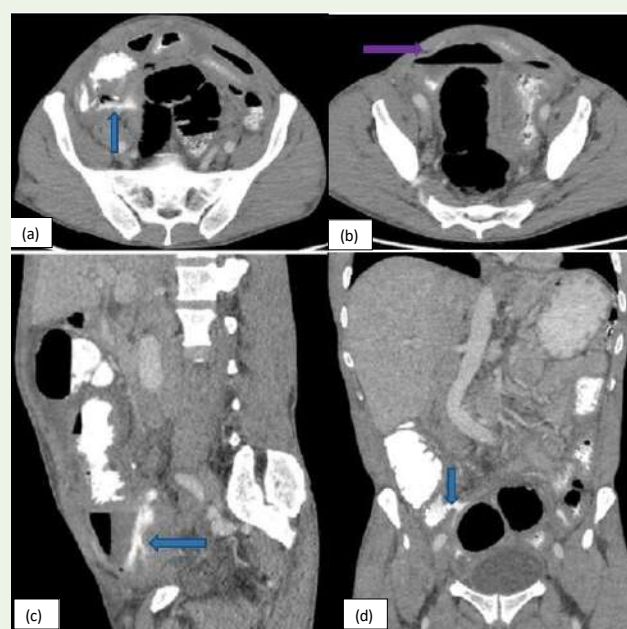
**Figure 2:** (a, b, c): Sagittal, Axial and coronal CT images of an 84-year-old female patient presented with acute non-localized abdominal pain. CT scan of the abdomen and pelvis with IV and oral contrast shows anastomotic sutures in the pelvis at the level of sigmoid colon, a loculated rim enhancing fluid collection in the recto-uterine pouch adjacent to the sigmoid anastomosis (green arrow), suggestive of anastomotic leak with an abscess.



**Figure 3:** (a, b, c, d): Sagittal, Axial and coronal CT images of a 43-year-old female, post laparoscopic sigmoid colectomy presents with abdominal pain and signs of sepsis. CT abdomen and pelvis with rectal contrast demonstrate extra luminal air loculi with mesenteric fat stranding (yellow arrow) adjacent to the sigmoid anastomosis (red arrow), suggestive of anastomotic leak with peritonitis in the lower pelvis. Additionally, reactive thickening of the sigmoid colon is noted.

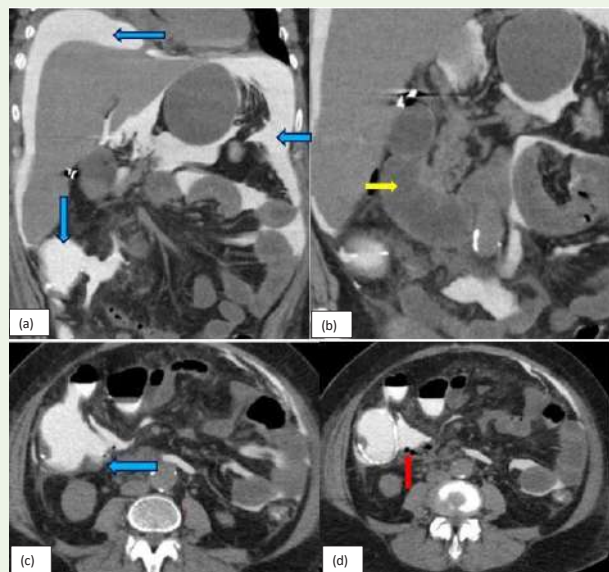


**Figure 4:** (a, b, c): Sagittal, Axial, and coronal CT images of a 71-year-old female with complaints of nausea and vomiting. CT scan of the abdomen and pelvis with oral contrast shows anastomotic sutures in the sigmoid colon, extra-luminal air loculi around sigmoid anastomosis with minimal extra luminal oral contrast (blue arrow), consistent with anastomotic leak.

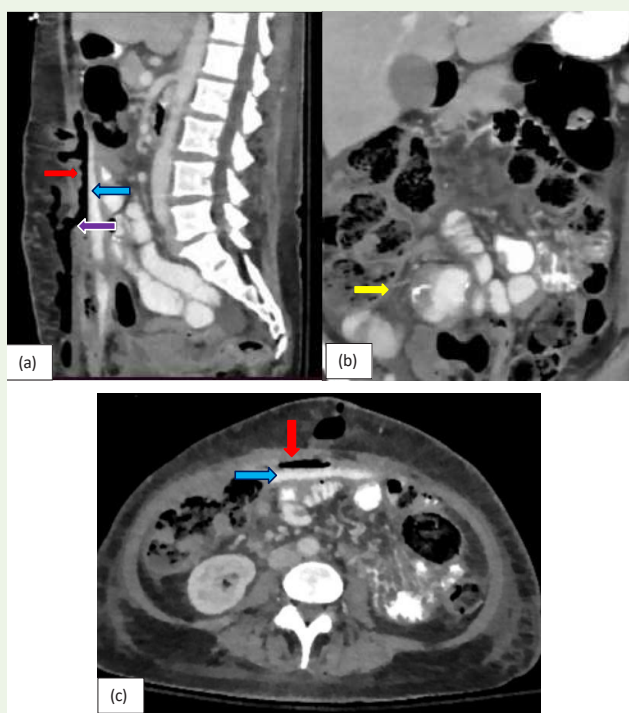


**Figure 5:** (a, b, c, d): Sagittal, Axial and coronal CT images of a 57-year-old male patient presents with lower abdominal pain. CT scan of abdomen and pelvis with oral and IV contrast shows extra-luminal extravasation of oral contrast adjacent to the ileocecal junction forming a focal collection with air fluid level in right lower quadrant of the abdomen (blue arrow), suggestive of anastomotic leak. Additionally, there is formation of another Extra-luminal collection with air-fluid level (purple arrow) is also seen in the pelvis suggestive of complications.

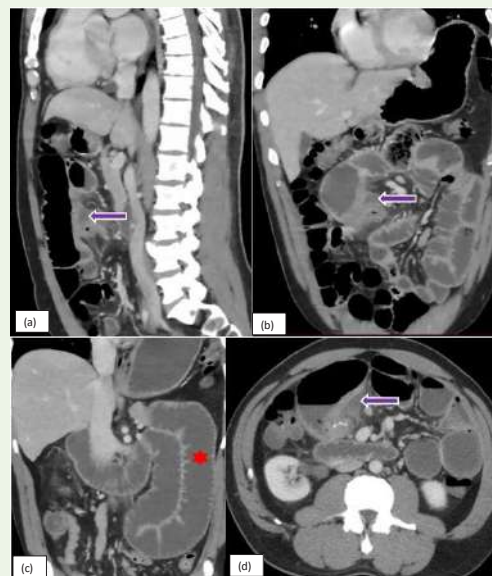




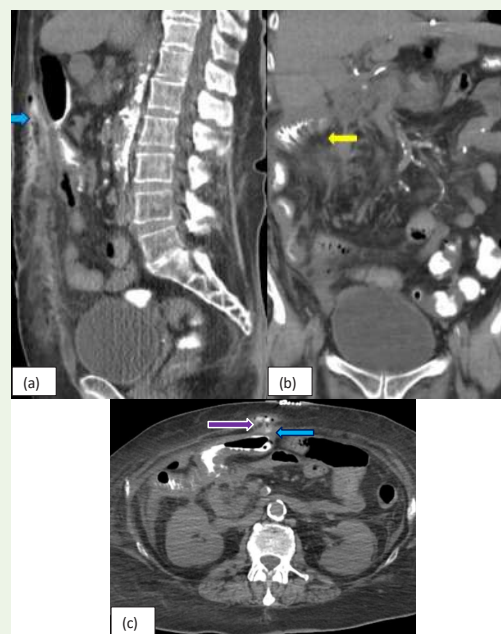
**Figure 6:** (a, b, c, d): Coronal and Axial CT images of a 59-year-old female, post right colectomy presents with acute pain abdomen. CT scan of the abdomen and pelvis with rectal contrast shows extra-luminal contrast (blue arrow) in the entire peritoneal cavity and air (red arrow) adjacent to the ascending colon, suggestive of an anastomotic leak. Also, Small bowel ileus/partial small bowel obstruction with diffuse mesenteric fat stranding (yellow arrow) is noted.



**Figure 7:** (a, b, c): Sagittal, coronal, and Axial CT images of a 53-year-old female presenting with signs of sepsis. CT scan of the abdomen and pelvis with oral and IV contrast demonstrates a large extra luminal complex fluid collection (blue arrow), large air loculi (red arrow) and mesenteric fat stranding (yellow arrow) in the anterior aspect of the abdomen, consistent with the anastomotic leak. There is fistulous communication of extra-vasated contrast (purple arrow) with the abdominal wall wound.



**Figure 8:** (a, b, c, d): Sagittal, coronal, and Axial CT images of a 42-year-old male with a past history of gunshot injury to the abdomen, post exploratory laparotomy presenting with acute upper abdominal pain, distension, nausea, vomiting, and diarrhea. CT scan of the abdomen and pelvis with IV contrast shows high-grade bowel obstruction (red star) with the transition to the level of jejunojejunal anastomosis in the mid abdomen. There is a small fluid collection adjacent to the anastomotic site (purple arrow), suggestive of anastomotic leak. In addition, adjacent bowel wall thickening suggestive of inflammation is noted.



**Figure 9:** (a, b, c): Sagittal, coronal, and Axial CT images of a 72-year-old female, post colectomy and gastric bypass present with wound infection. CT scan of the abdomen and pelvis with oral contrast shows extravasation of contrast (blue arrow) adjacent to the thickened small bowel loops with diffuse mesenteric fat stranding (yellow arrow) in the right anterior abdomen at the anastomotic site extending to the anterior abdominal wall, consistent with an anastomotic leak. Additionally, an entero-cutaneous fistula (purple arrow) forming localized collections in epigastric and umbilical regions is noted.

anastomotic leaks is to rule out if a leak exists. This helps in patient management including the need for repeat surgery versus watchful waiting. Hence, it is very important to determine the imaging findings that are most helpful in making an accurate diagnosis [1]. This pictorial review demonstrates findings helpful in making the diagnosis of an extraluminal air amount and fluid collection density anastomotic leak.

Extraluminal air was one of the most common findings seen on CT images. Anastomotic leaks with abscess formation were the second most common imaging finding, and studies show that it is mostly seen in patients with Crohn's disease [11]. The amount of extra-luminal air and density of fluid collection has no prognostic value wherein predicting an anastomotic leak [12]. Peritonitis was another most-seen imaging finding. In cases of free/generalized leak, there is complete dehiscence causing diffuse peritonitis due to contamination of the abdomen by bowel contents. In cases of the contained leak, there is limited contamination of the abdominal cavity with localized peritonitis. Free leakage can present with abdominal pain, fever, leucocytosis, hypotension, and altered mental state [13]. However, clinical features of contained leakage are non-specific, e.g. intestinal obstruction, fistulas, and pelvis abscess near anastomosis [14]. Contrast medium at the site of anastomosis is very important in detecting anastomotic leaks after colorectal surgeries [15].

## Conclusion

Anastomotic leak remains the main cause of morbidity and mortality after colorectal surgeries, and hence timely diagnosis and adequate treatment are important. Abdominal CT has become the method of choice for assessing anastomotic leaks. Identification of the most common CT findings helps in early detection in the early postoperative phase.

## References

1. Bahadurali Karim, Kielar Z A, Connolly Michael et al. (2018) Anastomotic Leaks After Small- and Large-Bowel Surgery: Diagnostic Performance of CT and the Importance of Intraluminal Contrast Administration. *AJR* 210: 1259-1265.
2. Daams F, Luyer M, Lange J (2013) Colorectal Anastomotic Leakage: Aspects of Prevention, Detection and Treatment. *World J Gastroenterol.* 19: 2293-2297.
3. Kulu Y, Ulrich A, Bruckner T, Contin P, Welsch T, et al. (2013) International Study Group of Rectal Cancer. Validation of the International Study Group of Rectal Cancer definition and severity grading of anastomotic leakage. *Surgery* 153: 753-761.
4. Smallwood N, Mutch MG, Fleshman JW (2014) The failed anastomosis. In: Steele SR, Maykel JA, Champagne BJ, Orangio GR, eds. *Complexities in Colorectal Surgery*. New York, NY: Springer-Verlag; 2014: 277-304.
5. Lim M, Akhtar S, Sasapu K, Harris K, Burke D, et al. (2006) Clinical and subclinical leaks after low colorectal anastomosis: a clinical and radiologic study. *Dis Colon Rectum* 49: 1611-1619.
6. Tan WP, Hong EY, Phillips B, Isenberg GA, Goldstein SD (2014) Anastomotic leaks after colorectal anastomosis occurring more than 30 days postoperatively: a single-institution evaluation. *Am Surg* 80: 868-872.
7. Boccola MA, Buettner PG, Rozen WM, Siu SK, Stevenson AR et al. (2011) Risk factors and outcomes for anastomotic leakage in colorectal surgery: a single-institution analysis of 1576 patients. *World J Surg* 35: 186-195.
8. McKenna NP, Bews KA, Cima RR, Crowson CS, Habermann EB (2020) Development of a risk score to predict anastomotic leak after leftsided colectomy: which patients warrant diversion? *J GastrointestSurg* 24: 132-143.
9. Gervaz P, Platon A, Buchs NC, Rocher T, Perneger T, et al. (2013) CT scan-based modelling of anastomotic leak risk after colorectal surgery. *Colorectal Dis* 15: 1295-300.
10. Byrne J, Stephens R, Isaacson A, Yu H, Burke C (2016) Image-guided Percutaneous Drainage for Treatment of Post-Surgical Anastomotic Leak in Patients with Crohn's Disease. *J Crohns Colitis* 10: 38-42.
11. Lynn ET, Chen J, Wilck EJ, El-Sabrouk K, Lo CC, et al. (2014) Radiographic findings of anastomotic leaks. *Am Surg* 79: 194-197.
12. Park EJ, Kang J, Hur H, Min BS, Baik SH, et al. (2018) Different clinical features according to the anastomotic leakage subtypes after rectal cancer surgeries: contained vs. free leakages. *PLoS One*.13: e0208572.
13. Yun JA, Cho YB, Park YA, Huh JW, Yun SH, et al. (2017) Clinical manifestations and risk factors of anastomotic leakage after low anterior resection for rectal cancer. *ANZ J Surg* 87: 908-914.
14. Huiberts AA, Dijkstra LM, Boer SA, Krul EJ, Peling J, et al. (2015) Contrast medium at the site of the anastomosis is crucial in detecting anastomotic leakage with CT imaging after colorectal surgery. *Int J Colorectal Dis* 30: 843-848.